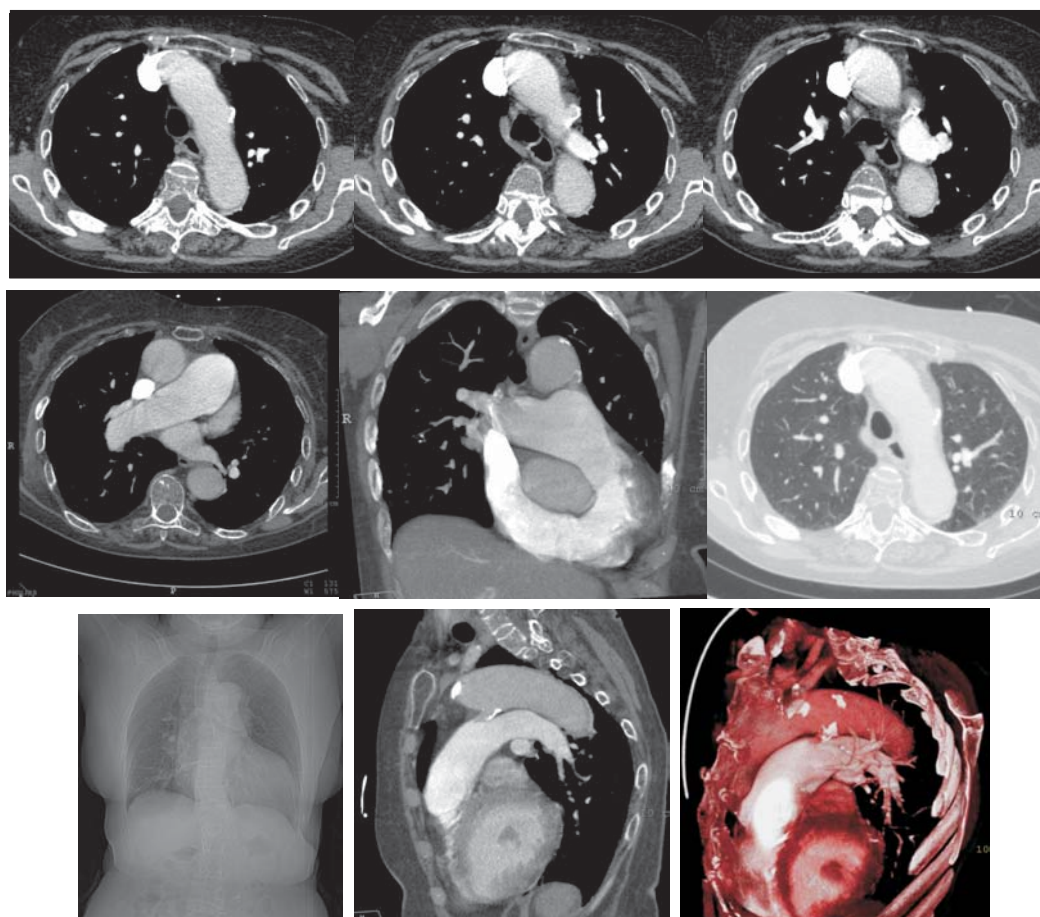


# Radiological Diagnosis

## We ask: What is the diagnosis?

DANY JASINOWODOLINSKI<sup>1</sup>, GUSTAVO DE SOUZA PORTES MEIRELLES<sup>2</sup>, NESTOR L MÜLLER<sup>3</sup>

A 73-year-old female patient with a history of metastatic colon cancer presented with dyspnea upon exertion, which had been gradually but progressively worsening for two years. Chest X-rays and computed tomography scans were obtained in order to perform a postoperative evaluation of the removal of the metastasis.



The objective of this section is stimulate an approach for the diagnosis based on clinical information and radiology. We invited all of the readers to participate. To answer it follows the instructions, click on the title of the question, and in the next screen it fills out the form with your diagnosis. Don't forget to identify the full name and institution the one that is linked. We published the names of who gets right the diagnosis. The shown images are the most important for the diagnosis. The diagnosis of that case will be published in the next number of the Journal.

1. Attending Radiologist at the Fleury Center for Diagnostic Medicine, São Paulo, São Paulo, Brazil

2. PhD in Radiology at the Universidade Federal de São Paulo (UNIFESP, Federal University of São Paulo), São Paulo, São Paulo, Brazil

3. Full Professor of Radiology at the University of British Columbia, Vancouver, British Columbia, Canada