

Free-hand placement of high thoracic pedicle screws with the aid of fluoroscopy

Evaluation of positioning by CT scans in a four-year consecutive series

Bruno Perocco Braga^{1,2}, Josaphat Vilela de Moraes², Marcelo Duarte Vilela³

ABSTRACT

Objective: To evaluate the feasibility, safety and accuracy of pedicle screw placement in the upper thoracic spine using the free-hand technique with the aid of fluoroscopy; to analyze the methods used to verify correct screw positioning intra and postoperatively.

Method: All patients with instability of the cervicothoracic or upper thoracic spine and at least one screw placed in the segment T1-T6 as part of a posterior construct entered the study. Only C-arm intraoperative fluoroscopy was used to guide screw placement.

Results: We obtained excellent positioning in 98.07% of the screws. CT scans precisely demonstrated pedicle wall and anterolateral body violations. There was no hardware failure, no neurological or vascular injury and no loss of alignment during the follow-up period.

Conclusion: Pedicle screws can be safely placed in the upper thoracic spine when strict technical principles are followed. Only a CT scan can precisely demonstrate vertebral body and medial pedicle cortical violations.

Key words: pedicle screws, transpedicular fixation, thoracic spine, cervicothoracic junction, spinal instability.

Colocação de parafusos pediculares na coluna torácica alta utilizando fluoroscopia: avaliação do posicionamento dos parafusos por tomografia computadorizada em uma série de casos durante quatro anos

RESUMO

Objetivo: Avaliar a factibilidade, segurança e eficácia da colocação de parafusos pediculares na coluna torácica alta utilizando apenas a fluoroscopia; analisar os métodos intra e pós-operatórios de verificação do posicionamento de parafusos. **Método:** Todos os pacientes com instabilidade da coluna cervico-torácica ou torácica alta e pelo menos um parafuso colocado no segmento T1-T6 foram incluídos no estudo. Apenas fluoroscopia intra-operatória foi utilizada para guiar a colocação dos parafusos. **Resultados:** Obtivemos excelente posicionamento em 98,07% dos parafusos. TC axial mostrou precisamente violações pediculares e da parede anterolateral do corpo vertebral. Não houve falência do instrumental, lesões neurológicas ou vasculares, ou perda do alinhamento sagital no período de seguimento. **Conclusão:** Os parafusos pediculares podem ser colocados com segurança na coluna torácica alta desde que técnicas operatórias precisas sejam executadas. Somente a TC pode demonstrar precisamente violações do corpo vertebral e da parede pedicular.

Palavras-chave: parafusos pediculares, fixação transpedicular, coluna torácica alta, junção cervico-torácica, instabilidade espinhal.

Correspondence

Marcelo Duarte Vilela
Rua Aimores 2480 / 1º andar
30140-072 Belo Horizonte MG - Brasil
E-mail: vilelamd@gmail.com

Received 27 October 2008
Received in final form 27 August 2009
Accepted 29 August 2009

¹Neurosurgeon, Hospital Mater Dei, Belo Horizonte MG, Brazil; ²Neurosurgeon, Hospital da Baleia, Belo Horizonte MG, Brazil; ³Assistant Professor, Department Of Neurological Surgery, Harborview Medical Center, University of Washington, Seattle WA, USA.

Techniques for stabilization of the thoracic spine have included the use of wires, hooks, rectangles, rods, plates, screws and combinations thereof. Theoretical advantages of pedicle screw fixation include three-column support¹⁻⁴ greater rotational stability^{5,6}, possibility of instrumentation in the absence of posterior column integrity¹⁻⁴, avoidance of neural canal dissection, decreased operative time^{3,5,7} and decreased blood loss⁷. More recently, superior efficacy of thoracic pedicle screws over other systems has been demonstrated⁵⁻⁹. They offer higher pull-out strength⁹, sustain greater loads to failure⁸ and facilitate a better correction of deformities⁵. Their use in the thoracic spine has already been described in the treatment of trauma^{2,4} deformities², spinal tumours² and infection-related instability². Nevertheless, their placement, especially in the upper thoracic segments, is not without hazards. There is risk of injury to the spinal cord, nerve roots, lung and vascular beds. Recently, some surgeons have advocated computer-assisted or three-dimensional systems to aid proper screw placement^{10,11}. In contrast, others have warranted safe positioning by use of only fluoroscopy and anatomic landmarks¹². The accuracy of thoracic screw placement, defined as screws placed totally within the pedicle, varies from 27.6% to 91.5%^{2,10,13,14}, even in the hands of experienced surgeons¹⁴. Interestingly enough, only a small number of complications from malpositioned screws have been reported^{2,4,5,13,15}. Most literature reports have not described the methods used to determine intraoperatively whether the screw position was considered accurate.

Therefore, this is the first study to evaluate screw positioning using CT scans in all patients and to correlate the CT findings with intraoperative fluoroscopy so as to establish criteria for the precise determination of screw positioning intraoperatively.

METHOD

Patient population and evaluation

During the four-year period from November 2003 through November 2007, all consecutive patients who had at least one thoracic pedicle screw placed in the upper thoracic spine (defined here as the segment from T1 through T6) entered the study (Table 1). All were rated according to the ASIA classification (Table 2). Imaging studies consisted of at least AP and lateral radiographs and computed tomographic scanning in all patients. MRI was obtained for neoplasms, infectious diseases, cervicothoracic spine injuries or when the neurological examination did not accurately correspond to the level of injury. Surgical indications included patients with neurologic deficits with the exception of a nerve root lesion, significant anterior spinal cord compression, vertebral body collapse and kyphotic deformities of more than 35 degrees, and flexion-distraction or flexion-dislocation injuries (types B or type C).

All patients were available for follow-up, which ranged from five to 34 months. All patients had a CT scan performed no more than three days postoperatively to confirm adequate placement of the screws. All but 2 patients with neoplastic lesions wore either a TLSO or a CTLSO postoperatively for at least 12 weeks. Stability was documented on an upright x-ray without the orthosis, performed during follow-up to verify maintenance of alignment. The study was analyzed and approved by the hospitals ethics committees.

Operative technique

A three-point head holder was used in all cases. After adequate exposure, the entry point for the pedicle screws was defined as the intersection of a horizontal line passing through the superior margin of the transverse process

Table 1. Number of screws per level instrumented.

Level instrumented	T1	T2	T3	T4	T5	T6
Number of screws	58	50	66	84	82	75

Table 2. ASIA status pre and postoperatively.

Preoperative ASIA	Postoperative ASIA				
	A	B	C	D	E
A	35	35			
B	4	2		1	1
C	4		1	2	1
D	16			6	10
E	22				22
Unknown	2				2
Total	83	35	2	9	36

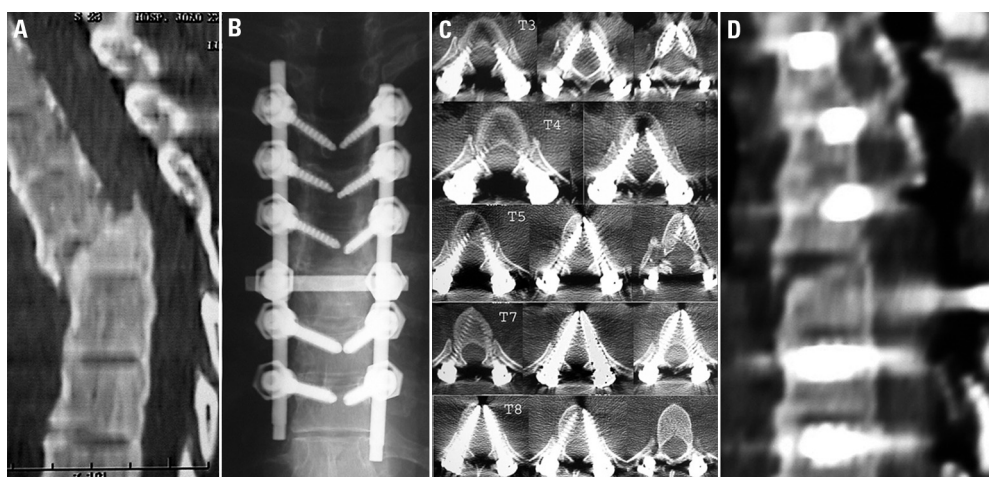


Fig 1. Images of patient # 6: a 50-year-old female collided her motorcycle against a deer and was admitted paraplegic. [A] Preoperative CT scan showing a T5-T6 fracture-dislocation with marked anterolisthesis and kyphotic deformity. [B] Postoperative X ray showing good coronal alignment and good screw positioning. [C] Postoperative CT scans confirming optimal placement of pedicle screws at all levels instrumented, from T3-T5 and T7-T8. [D] Postoperative CT scan showing complete reduction and restoration of normal sagittal alignment.

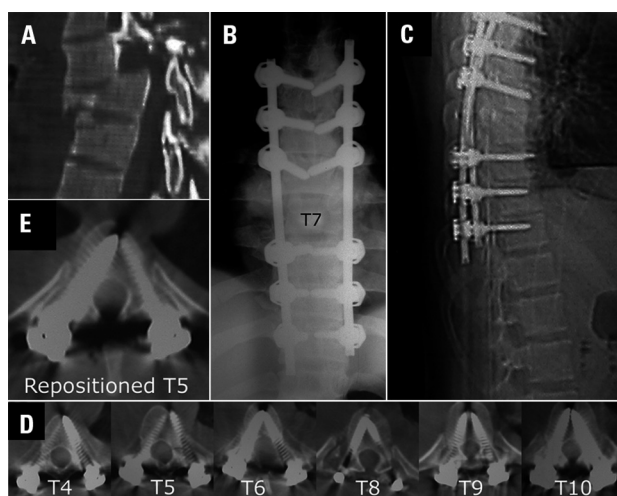

Fig 2. Images of patient #27: this 32-year-old male sustained a T6-T7 fracture-dislocation. [A] Preoperative CT scan showing a T6-T7 fracture-dislocation with marked anterolisthesis and kyphotic deformity. [B] Postoperative X ray showing good coronal alignment and good screw positioning. [C] Postoperative X ray showing good sagittal alignment and good screw positioning. [D] Postoperative CT scans confirming optimal placement of pedicle screws at all levels instrumented, from T4-T6 and T8-T10, with the exception of the left T5 screw, which perforated the anterolateral cortex and put the aorta at risk. [E] CT scan after repositioning of left T5 screw showing adequate placement.

and a vertical line passing 3 mm medial to the lateral border of the superior facet. A pedicle probe was carefully advanced under fluoroscopic guidance in the straight-forward or anatomical trajectory¹⁶. At least 80% of the vertebral body was cannulated using the pedicle probe so as to place the longest screw possible, taking care not to perforate the anterior cortex. In all cases we only used lateral

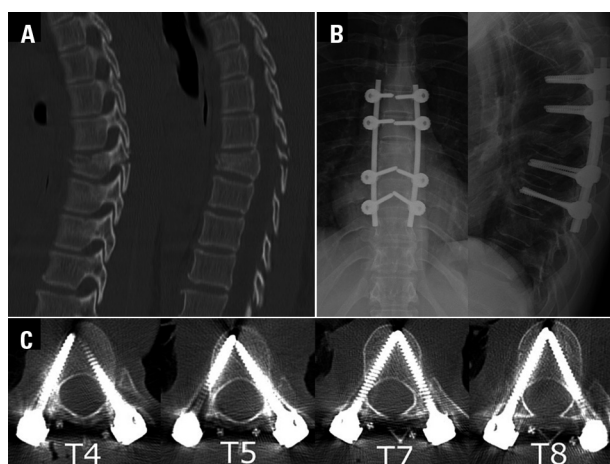


Fig 3. Images of patient # 12: a 16-year-old girl was involved in a motor-vehicle accident and was admitted complaining of back pain (ASIA E). [A] Preoperative CT scan showing a T5-T6 flexion-distraction injury with kyphotic deformity. [B] Postoperative X rays showing good coronal and sagittal alignment and good screw positioning. [C] Postoperative CT scans confirming optimal placement of pedicle screws at all levels instrumented, from T4-T5 and T7-T8.

fluoroscopic imaging and anatomical landmarks as guides to cannulate the pedicle and vertebral body.

For patients with very narrow pedicles, we used the technique of placing the screws with the entry point inside the costovertebral joint. For the latter, the entry point was usually 2 mm lateral to the lateral edge of the superior facet, converging more medially than the usual technique for that level.

A small ball-tip probe was used to confirm pedicle and vertebral body walls integrity and measure the length of the screw. Self-tapping titanium screws mea-

suring from 3.5 to 6.25 mm were inserted. We only used 3.5 mm screws when the construct crossed the cervico-thoracic junction. When the construct was sited just on the thoracic spine, the smallest screw used was 5.5 mm. The screws were inserted using the same angulation used to cannulate the vertebral body.

In those patients in whom a costotransversectomy was done, the rod was placed on the left side first and then a vertebrectomy with its substitution for a cage with either bone graft (in infection or trauma) or cement (in tumours) was done, prior to placement of the right rod. Anteroposterior fluoroscopy was then used to confirm correct screw positioning and coronal alignment.

RESULTS

A total of 415 pedicle screws were placed in 83 patients (Table 1). Neurological status improved in 10 out of 16 patients with incomplete injuries and no worsening of function was observed (Table 2). All patients had satisfactory correction of the deformity confirmed both intra and postoperatively, with no loss of correction or hardware failure on subsequent follow-up.

Adequate placement was accomplished in 407 screws, giving a correctness rate of 98.07%. Screw placement was verified with postoperative CT scan in all cases. It was considered adequate if the screw did not perforate the anterolateral cortex of the vertebral body more than 4 mm and did not violate the medial pedicle wall more than 2 mm or did not result in neurological deficits or vascular lesion. Five screws violated the spinal canal consequent to medial wall penetration of 3-4 mm, but did not result in cerebrospinal fluid leak or neurological deficit; although not considered adequate, they were still considered acceptable and we did not reposition them. We did not consider pure lateral pedicle wall violations to be of significance. Two patients (one screw each) had screws with their tips lateral to the vertebral body but were not considered to be posing a high risk (less than 3 mm perforation) and therefore not repositioned. Both patients remain well twenty six months after surgery. One screw in patient 28 was repositioned because it had perforated the anterolateral vertebral cortex more than 4mm and was abutting the aorta. There were 7 cases of superficial wound infection, including one of them who had meningitis; all were cured with antibiotics and debridement. One patient (#31) died fourth months after surgery following deep vein thrombosis and pulmonary embolism. No loss of correction, hardware failure or instability was noted during follow-up.

Verification of screw positioning

We analyzed the postoperative CT scans and retrospectively correlated those with the intraoperative AP

and immediate postoperative AP and lateral x-rays. On the intraoperative AP images the screw tips should be aligned with the lateral cortex of the spinous process for the screw position to be considered excellent. This almost always ensures that the screw tip has not perforated the anterolateral cortex of the vertebral body and is not too medial, provided it is not too long on the lateral x-ray. When the screw tip crosses to the other side of the midline, the screw may be too medial, violating the medial pedicle wall, and probing of the track should be performed. It is important to note that even if the screw tip is not crossing the midline on the AP images, if the entry point is too medial, the screw may be traversing the spinal canal. Therefore, strict attention to the entry point is of utmost importance. Sometimes the midline orientation is lost, especially when a laminectomy has been performed or when the spinous processes are fractured. Additionally, rotational deformities in fracture dislocations may also disorient the midline. In those cases, it is difficult to evaluate the position of the screws on the AP image. It is always a good idea to draw an imaginary line from the spinous process above the instrumentation to the spinous process below the instrumentation and correlate that with the screw position.

We have observed that it is very difficult to clearly state whether the screws have perforated the anterolateral cortex of the vertebral body using only AP images, especially when the screw is not aligned with the lateral cortex of the spinous process. In those cases, one must review the preoperative axial CT scans and determine the relationship between the anterolateral vertebral body cortex and the pedicle walls. If, on the preoperative CT scan, the anterolateral cortex is medial to the medial wall of the pedicle (triangular-shaped vertebral body), then the entire screw tip must be placed medial to the medial pedicle wall line on a perfect AP image. If, on the preoperative CT, the anterolateral vertebral body cortex is lateral to the lateral pedicle wall (round shaped vertebral body), the entire screw tip should be at least medial to the lateral pedicle wall. One should account for the screw length and diameter.

Case examples

Patient 06 – A 50-year-old female was involved in a motorcycle accident and sustained a complete spinal cord injury (ASIA A). CT scan showed marked T5-T6 fracture-dislocation, with striking anterolisthesis and severe kyphotic deformity. She underwent a posterior segmental instrumentation using 5.5 mm pedicle screws at T3 through T8 with excellent deformity correction and screw positioning (Fig 1).

Patient 27 – This 32-year-old male sustained a T6-T7 fracture-dislocation. Intraoperative imaging demonstrated good alignment of the screws in relation to the

spinous processes, a feature seen as well in the postoperative x-rays. Postoperative CT, however, showed the left screw at T5 had penetrated the anterolateral cortex and was in close contact with the aorta. The screw was repositioned (Fig 2).

Patient 12 – A 16-year-old girl was involved in a motor-vehicle accident and was admitted complaining of back pain (ASIA E). A T5-T6 flexion-distraction was visualized on imaging studies. A T4 through T8 posterior segmental instrumentation was performed, with good correction of the deformity and excellent screw positioning (Fig 3).

DISCUSSION

Technical advantages of pedicle screws in the thoracic spine include avoidance of neural canal dissection, decreased operative time^{3,5,7} and less blood loss⁷. Biomechanical advantages include three-column support¹⁻⁴, possibility of instrumentation in the absence of posterior column integrity¹⁻⁴ and greater rotational stability in the transverse axis^{5,6}. An additional benefit from a screw-rod construct is the use of cross-links, forming a triangle in the transverse plane, which significantly improves screw pullout strength and rotational and lateral bending stiffness^{17,18}. Despite the narrowness of thoracic pedicles, placing screws with diameters greater than the pedicle itself has already been proven safe and efficacious²; and it is known that the greater the minor screw diameter the greater the bending strength and the larger the major screw diameter the greater the pullout strength¹⁹.

Placing pedicle screws in the upper thoracic spine is hazardous. Penetration of the medial pedicle wall may injure the spinal cord or dura-mater; inferior penetration may harm the nerve roots, lateral violation may damage the lung, vessels and/or sympathetic chain and perforation of the anterolateral vertebral body may also cause lesion to the great vessels and esophagus¹⁴.

The short and triangular vertebral bodies and thin and medially oriented pedicles from T1 to T6 are the major factors responsible for the difficulties in the technique of placing upper thoracic pedicle screws. Anatomic studies determined the thinnest pedicles to be between T3 and T6 (from 4.5 to 5.1 mm), compared with mean widths of 5.9 to 6.5 mm for T1-T2^{3,6,20}, and the pedicle transverse angle to be greatest at T1 and T2, measuring 28.2° and 16.6°, respectively^{2,20}. In order to overcome these difficulties, it is important to know the safe margins of cortical violation. In the upper thoracic spine, the closest distance between the aorta and the vertebral body is 6 mm, at T4 through T6²¹. Between the pedicle and the dural sac, Uğur reported no distance from T3 to T6 and only 0.5 and 0.2 mm of distance at T1 and T2, respectively³.

Attempting to bypass the challenges of narrow pedi-

cle screw fixation in the thoracic spine, an extrapedicular technique has been described by Husted¹. In fact, we used this technique in two children, allowing the use of 5.5 mm screws in the pedicles of T3 through T5.

Probing the pedicle tract is the only way to assess proper screw placement prior to its insertion; it is the only method that can actually prevent misplacement²². Nonetheless, even in the hands of an experienced thoracic spine surgeon, it has an accuracy of 82%, sensitivity of 81% and specificity of 93%, with medial wall violations being the most difficult to assess²². We found that when probing one pedicle if the surgeon feels the tip of the contralateral screw and there is no anterior wall violation, for sure both screws are in the vertebral body; one screw might be too medial, though, especially if it measures longer than the contralateral one.

The most difficult but also most important step in cannulating the vertebral body is to correctly aim the probe medially. It is more difficult to cannulate the pedicles when using the pointing down technique, since the smallest diameter of the vertebral body is at the mid-portion of the body. The widest diameter is close to the disc space and therefore our preference is to cannulate using the straight technique, with the probe being parallel to the endplate, which is also better biomechanically¹⁶.

After surgery, x-rays and computed tomography scans can be used to confirm correct positioning of screws. Plain film accuracy depends on the experience of the interpreter, varying from 73% to 83%²³. Routine anteroposterior and lateral views are inadequate to evaluate screw position^{23,24}. CT is the most accurate study; however, its sensitivity and specificity varied from 76% to 86% and 75% to 88%, respectively²⁵⁻²⁷. Inferior wall violations are the most difficult to detect on CT scans²⁵.

It is our opinion that the only way to accurately demonstrate a satisfactory placement of thoracic screws is using postoperative CT scans; medial and lateral violations can be easily seen with this technique. Violations that put risk to either neurological or visceral structures are the anterolateral vertebral body and medial pedicle wall. Therefore, only these two types of violation were considered to be of significance in our patients. We did not think that spinal canal violations up to 2 mm were significant. They did not cause any neurological deficits and there was no instance of a cerebrospinal fluid leak. Violations of 1-2 mm may be difficult to distinguish from artifacts caused by the implant²⁸. Pedicle screw violations of 1-2 mm have spinal canal intrusion volumes smaller than a standard pedicle hook or a laminar hook⁷. A pedicle screw has actually to cause a 3 mm violation to have an intrusion volume equivalent to what seen with a perfectly placed adult laminar hook⁷. For those reasons, spinal canal violations of up to 2 mm are not considered sig-

nificant by others as well^{13,28,29} and a 4 mm safe zone has been suggested by some as the upper limit of intraspinal violation²⁹. Inferior pedicle wall violations should be rare since the entry point is on the upper half of the pedicle but should always be checked, especially at the T1 level.

We believe the free hand technique by use of thorough knowledge of the spinal anatomy, judicious exposure and standard fluoroscopy suffice for the correct positioning of transpedicular screws in the upper thoracic spine. Image-guided systems can surely improve the accuracy of pedicle screw placement¹⁰, but the clinical outcome as evaluated by vascular and neurological complications, correction of deformities and hardware failure seems to be unaffected, as shown in our own study and in several series in which only fluoroscopic imaging or radiographs were used^{2,4,5,13,30}. The extra surgical time and cost demanded by these new technological devices may thus not justify their use in substitution of an old established technique that produces the same clinical results.

Although other studies have shown that thoracic pedicle screws are safe and feasible, this is the first that attempts to correlate intraoperative images with postoperative CT scans so as to accurately identify whether a screw is accurately positioned or not.

In conclusion, pedicle screws ease better correction of spinal deformities and provide greater stability than other fixation systems, mainly through their ability to provide three-column support and rotational rigidity. Attention to anatomical landmarks and entry points, proper medial angulation and careful palpation of the pedicle tract are essential for adequate placement. Satisfactory placement by use of the free hand technique with the aid of standard fluoroscopy can be achieved in practically all cases with a minimal incidence of screw malpositioning. Only CT scans can accurately identify anterolateral vertebral body and medial pedicle wall violations. Correlation of the intraoperative fluoroscopic images with the preoperative axial CT scan images helps confirming adequate screw positioning intraoperatively. Despite the technical difficulties and risks of injury to critical surrounding structures, the use of pedicle screws in the upper thoracic spine can be done with great efficacy and safety.

REFERENCES

- Husted DS, Yue JJ, Fairchild TA, Haims AH. An extrapedicular approach to the placement of screws in the thoracic spine: an anatomic and radiographic assessment. *Spine* 2003;28:2324-2330.
- Kuntz IV C, Maher PC, Levine NB, Kurokawa R. Prospective evaluation of thoracic pedicle screw placement using fluoroscopic imaging. *J Spinal Disord Tech* 2004;17:206-214.
- Uğur HÇ, Attar A, Uz A, Tekdemir I, Egemen N, Genç Y. Thoracic pedicle: surgical anatomic evaluation and relations. *J Spinal Disord* 2001;14:39-45.
- Yue JJ, Sossan A, Selgrath C, et al. The treatment of unstable thoracic spine fractures with transpedicular screw instrumentation: a 3-year consecutive series. *Spine* 2002;27:2782-2787.
- Suk SI, Lee CK, Min HJ, Cho KH, Oh JH. Comparison of Cotrel-Dubousset pedicle screws and hooks in the treatment of idiopathic scoliosis. *Int Orthop* 1994;18:341-346.
- Vaccaro AR, Rizzolo SJ, Allardice TJ, et al. Placement of pedicle screws in the thoracic spine - part 1: morphometric analysis of the thoracic vertebra. *J Bone Joint Surg (Am)* 1995;77:1193-1199.
- Polly DW, Potter BK, Kuklo T, Young S, Johnson C, Klemme WR. Volumetric spinal canal intrusion: a comparison between thoracic pedicle screws and thoracic hooks. *Spine* 2003;29:63-69.
- Heller JG, Shuster JK, Hutton WC. Pedicle and transverse process screws of the upper thoracic spine: biomechanical comparison of loads to failure. *Spine* 1999;24:654-658.
- Liljenqvist UR, Hackenberg L, Link TM, Halm H. Pullout strength of pedicle screws versus pedicle and laminar hooks in the thoracic spine. *Acta Orthop Belg* 2001;67:157-163.
- Youkilis AS, Quint DJ, McGillicuddy JE, Papadopoulos SM. Stereotactic navigation for placement of pedicle screws in the thoracic spine. *Neurosurgery* 2001;48:771-779.
- Schwarzenbach O, Berlemann U, Jost B, et al. Accuracy of computer-assisted pedicle screw placement: an in vivo computed tomography analysis. *Spine* 1997;22:452-458.
- Carbone JJ, Tortolani J, Quartararo LG. Fluoroscopically assisted pedicle screw fixation for thoracic and thoracolumbar injuries. *Spine* 2003;28:91-97.
- Belmont Jr PJ, Klemme WR, Dhawan A, Polly Jr DW. In vivo accuracy of thoracic pedicle screws. *Spine* 2001;26:2340-2346.
- Vaccaro AR, Rizzolo SJ, Balderston RA, et al. Placement of pedicle screws in the thoracic spine. Part 2: An anatomical and radiographic assessment. *J Bone Joint Surg (Am)* 1995;77:1200-1206.
- Heini P, Scholl E, Wyler D, Stefan E. Fatal cardiac tamponade associated with posterior spinal instrumentation: a case report. *Spine* 1998;23:2226-2230.
- Lehman RA, Polly DW, Kuklo TR, Cunningham B, Kirk KL, Belmont Jr PJ. Straight forward versus anatomic trajectory technique of thoracic pedicle screw fixation: a biomechanical analysis. *Spine* 2003;28:2058-2065.
- Carson WL, Duffield RC, Arendt M, Gaines Jr RW. Internal forces and moments in transpedicular spine instrumentation: the effect of pedicle screw angle and transfixation: the 4R-4Bar linkage concept. *Spine* 1990;15:893-901.
- Ruland CM, McAfee PC, Warden KE, Cunningham BW. Triangulation of pedicular instrumentation: a biomechanical analysis. *Spine* 1991;16:270-276.
- Krag M. Biomechanics of thoracolumbar spinal fixation: a review. *Spine* 1991;16:84-99.
- Zindrick MR, Wiltse LL, Doornik A, et al. Analysis of morphometric characteristics of the thoracic and lumbar pedicles. *Spine* 1987;12:160-166.
- Liljenqvist UR, Allkemper T, Hackenberg L, Link TM, Steinbeck J, Halm HFH. Analysis of vertebral morphology in idiopathic scoliosis with use of magnetic resonance imaging and multiplanar reconstruction. *J Bone Joint Surg* 2002;84:359-368.
- Lehman RA, Potter BK, Kuklo TR, et al. Probing for thoracic pedicle screw tract violation(s): is it valid? *J Spinal Disord Tech* 2004;17:277-283.
- Ferrick MR, Kowalski JM, Simmons Jr ED. Reliability of roentgenogram evaluation of pedicle screw position. *Spine* 1997;22:1249-1253.
- Weinstein JN, Spratt KF, Spengler D, Brick C, Reid S. Spinal pedicle fixation: reliability and validity of roentgenogram-based assessment and surgical factors on successful screw placement. *Spine* 1988;13:1012-1018.
- Fayyazi AH, Hugate RR, Pennypacker J, Gelb DE, Ludwig SC. Accuracy of computed tomography in assessing thoracic pedicle screw malposition. *J Spinal Disord Tech* 2004;17:367-371.
- Rao G, Brodke DS, Rondina M, Dailey AT. Comparison of computerized tomography and direct visualization in thoracic pedicle screw placement. *J Neurosurg* 2002;97:223-226.
- Yoo JU, Ghanayen A, Petersilge C, Lewin J. Accuracy of using computed tomography to identify pedicle screw placement in cadaveric human lumbar. *Spine* 1997;22:2268-22671.
- Belmont Jr PJ, Klemme WR, Robinson M, Polly Jr DW. Accuracy of thoracic pedicle screws in patients with and without coronal-plane deformities. *Spine* 2002;27:1558-1566.
- Gertzbein SD, Robbins SE. Accuracy of pedicular screw placement in vivo. *Spine* 1990;15:11-14.
- Bransford R, Bellabarba C, Thompson JH, Henley MB, Mirza SK, Chapman JR. The safety of fluoroscopically-assisted thoracic pedicle screw instrumentation for spine trauma. *J Trauma* 2006;60:1047-1052.