

## INVOLUNTARY MOVEMENTS AND AIDS

### REPORT OF SEVEN CASES AND REVIEW OF THE LITERATURE

JAMES PITÁGORAS DE MATTOS \*, ANA LÚCIA Z. ROSSO \*\*,  
ROSALIE BRANCO CORRÊA \*\*, SÉRGIO NOVIS \*\*\*

---

**SUMMARY** — We studied 1086 AIDS patients in the last six years. Of these 389 (35.82%) had neurological manifestation and 7 (1.8%) male patients had abnormal involuntary movements (parkinsonism in 3, hemichorea-hemiballism in 2, spinal myoclonus in 1 and rubral tremor in another). All patients were men, 5 white and 2 black. Four were homosexual, 2 drug-users and 1 bisexual. The mean age was 33.14 years. The time between AIDS diagnosis and the onset of movement disorders was 23.8 months in 5 patients and in 2 it was the first symptom. The parkinsonian patients did not show any opportunistic infection in connection with the neurological symptoms but in the remaining four cases this relationship was suggested. The data showed that not only the opportunistic infection but also the AIDS virus may play an important role on the development of involuntary movements.

**KEY WORDS:** movement disorders, AIDS, toxoplasmosis, parkinsonism.

#### Movimentos involuntários e AIDS: relato de sete casos e revisão da literatura.

**RESUMO** — Nos últimos 7 anos, estudamos a incidência de movimentos involuntários anormais em 1086 pacientes com AIDS. Destes, 389 (35,82%) tinham manifestações neurológicas e 7 (1,8%) apresentaram movimentos involuntários anormais. Todos eram homens, com média de idade de 33,14 anos. O tempo médio entre o diagnóstico de AIDS e o início dos movimentos involuntários foi 23,8 meses em 5 pacientes. Nos 2 casos restantes, os movimentos anormais inauguraram o quadro de AIDS. Três pacientes apresentaram parkinsonismo, 2 hemicoréia-hemibalismo, 1 mioclonia medular e 1 tremor rubral. Quatro eram homossexuais, 2 usuários de drogas endovenosas e 1 bissexual. Infecção oportunista em atividade não foi evidenciada na época do aparecimento dos sintomas parkinsonianos em 3 pacientes, porém, no restante, sua presença foi confirmada (toxoplasmose cerebral em 2, tuberculose em 1 e co-infecção por toxoplasmose e tuberculose em outro). Os dados mostram que, não só as infecções oportunistas, mas também o vírus HIV pode desempenhar importante papel na gênese dos movimentos involuntários.

**PALAVRAS-CHAVE:** desordens do movimento, AIDS, toxoplasmose, parkinsonismo.

---

Neurological involvement in patients with acquired immune deficiency syndrome (AIDS) ranges from 21 to 40%<sup>6,17</sup> but on autopsy studies it may grow over 70%<sup>6</sup>. Involuntary movements in AIDS patients are relatively uncommon. It became more evident in the last years with the reports of Navia et al.<sup>11,12</sup>, Martinez-Martin<sup>7</sup> and Nath et al.<sup>10</sup>. According to Singer et al.<sup>15</sup> and Nath et al.<sup>10</sup>, movement disorder represent 11% of AIDS patients with involvement of the nervous system. Several movement disorders have been described, such as hemi-

---

Serviço de Neurologia, Setor de Doenças Extrapiramidais, Hospital Universitário Clementino Fraga Filho, (HUCFF). Universidade Federal do Rio de Janeiro (UFRJ). \* Professor Adjunto, Chefe de Setor; \*\* Médica; \*\*\* Professor Titular, Chefe de Serviço. Aceite: 18-março-1993.

Dr. James Pitágoras de Mattos — Av. São Sebastião 165/101 - 22291-070 Rio de Janeiro RJ - Brasil.

chorea-hemiballism <sup>1,3,7,9,10,12-15</sup>, myoclonus <sup>10,11</sup>, dystonia <sup>8,10,18</sup>, parkinsonism <sup>2,8,10</sup>, tremor <sup>5,10,11,15</sup> and cerebellar ataxia <sup>15</sup>.

The objective of this work is to report seven cases of AIDS-related abnormal involuntary movements.

### MATERIAL AND METHODS

We studied 1086 AIDS patients during the last 7 years (1986 to 1992) from the HUCFF-UFRJ. Of these patients, 389 (35.82%) had neurological manifestations and 7 (1.8%) had involuntary movements (parkinsonism in 3, hemichorea-hemiballism in 2, spinal myoclonus in 1 and rubral tremor in another). All patients were men, 5 white and 2 black. The mean age was 33.14 years. Four were homosexual, 2 drug-users and 1 bisexual. The mean time between AIDS diagnosis and the onset of the movement disorder was 23.8 months in 5 patients, and in 2 this was the first symptom.

Clinical data of the patients are summarized in the Table.

### CASE REPORTS

Patient 1. IMA, a 31-year-old bisexual man was admitted because of abrupt onset of choreic movements in the left limbs and intracranial hypertension. The CT scan showed lesions with ring enhancement in both frontal lobes (Fig. 1 A and B). The diagnosis of toxoplasmosis abscess was suspected and treatment with sulfadiazine and pyrimethamine was initiated. The HIV antibody test was positive and 2 weeks later a new CT scan showed a marked improvement of the lesions (Fig. 1 C and D). The abnormal involuntary movements did not improve with the use of neuroleptics. Four months after the first symptom he died of respiratory failure and sepsis.

Patient 2. RSF, a 40-year-old homosexual man presented with ganglionic tuberculosis in 1968 and the diagnosis of AIDS was made. In 1991, he noticed rest tremor in the hands and gait disturbances. The neurologic examination showed masked face, left hand rest and action tremor, rigidity more severe on the left side and impaired balance. There was no history of prior neuroleptic exposure. The CT scan showed diffuse atrophy. He was treated with levodopa with a marked improvement of the parkinsonian signs. The treatment had to be stopped because of severe levodopa side effects. The clinical picture deteriorated progressively, he became demented and died one year later from sepsis.

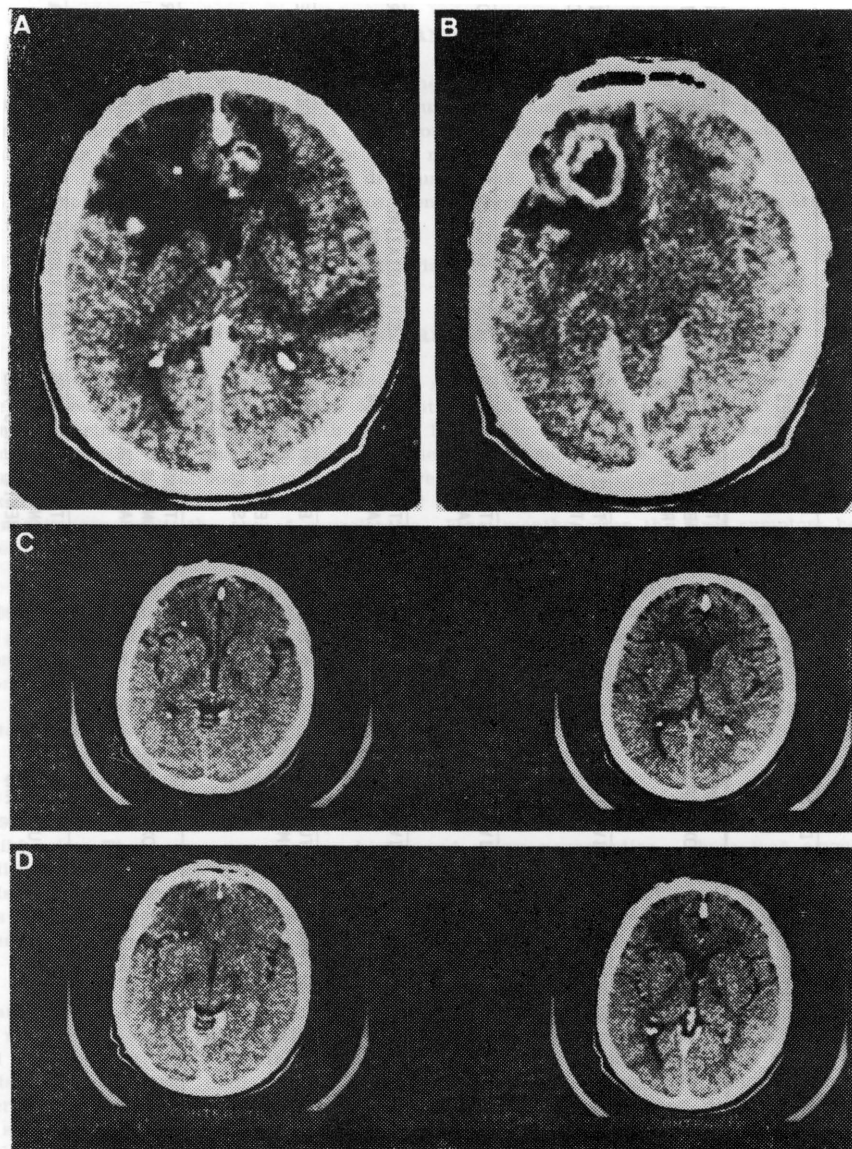
Patient 3. FJC, a 33-year-old homosexual man received the diagnosis of AIDS in 1987. In 1988 he had the diagnosis of cryptococcal meningitis. Three years later he started having bradikinesia. There was no previous history of using neuroleptics. There was asymmetric rigidity more evident on the left side, facial akinesia and postural and kinetic tremor of the hands. The CT scan showed bilateral basal ganglia calcification. This was absent in a previous CT four months before. The levodopa treatment was not tolerated although some improvement of the bradikinesia was noted. He died one year later from sepsis.

Patient 4. CPL, a 31-year-old drug-user man had disseminated tuberculosis in 1991 and an anti-HIV test was positive. Seven months later the diagnosis of toxoplasmosis abscess was made and he was treated with sulfadiazine and pyrimethamine with clinical and radiological improvement. Two months later he developed severe bradikinesia and tremor in the hands. He had never used neuroleptic drugs before. The neurologic examination showed generalized rigidity, marked bradikinesia, rest tremor of the hands and drooling mouth. The CT scan showed bilateral basal ganglia calcification and diffuse atrophy. Treatment with levodopa was initiated with marked improvement of the parkinsonian signs.

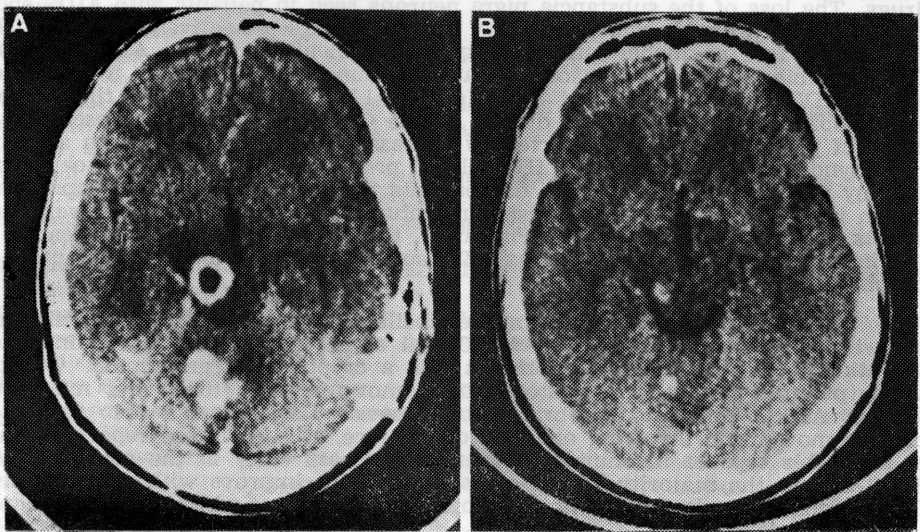
Patient 5. LMS, a 28-year-old drug-user man was admitted because of renal tuberculosis and an anti-HIV test was positive. He developed progressive paraparesis. The neurologic examination showed a flacid paraplegia, a sensory level at D10, bilateral Babinski sign, deep general areflexia and myoclonic jerks in the lower limbs. The EEG was normal. The ENMG study revealed a radiculopathy. The CSF study showed 15 cells (78% mononuclear), 257 mg% of proteins, 50 mg% of glucose. The bacteriologic study demonstrated tubercle bacilli. Anti-herpes simplex test was positive, anti-CMV was positive for IgG and the anti-HIV test was positive. The diagnosis of tuberculous myelopathy was considered and a treatment with

Table. Clinical features, diagnostic procedures and outcome of 7 patients with involuntary movement.

PATIENT	AGE	AIDS RISK PRACTICES	INVOLUNTARY MOVEMENT	DIAGNOSIS	TIME OF THE ONSET OF THE INVOLUNTARY MOVEMENT	DIAGNOSTIC PROCEDURES	OUTCOME
1 (IMA)	31	BISEXUAL	LEFT HEMICHOREA-HEMIBALLISM	CNS TOXOPLASMOSIS	NONE	CT: TOXOPLASMOSIS ABSCESS IN BOTH FRONTAL LOBES	SULFADIAZINE+PYRIMETHAMINE IMPROVED THE CT APPEARANCE BUT NOT THE INVOLUNTARY MOVEMENT. DEATH OCCURED 6 MONTHS LATER.
2 (RSF)	40	HOMOSEXUAL	PARKINSONISM	HIV VIRUS (?)	3 YEARS	CT: DIFFUSE ATROPHY	THE PARKINSONISM RAPIDLY DETERIORATED FOLLOWED BY DEMENTIA. DEATH OCCURED ONE YEAR LATER.
3 (FJC)	33	HOMOSEXUAL	PARKINSONISM	HIV VIRUS (?)	4 YEARS	CT: BASAL GANGLIA CALCIFICATION	DEATH OCCURED 5 YEARS AFTER AIDS DIAGNOSIS.
4 (CPL)	31	DRUG-USER	PARKINSONISM	HIV VIRUS (?)	9 MONTHS	CT: BASAL GANGLIA CALCIFICATION	SULFADIAZINE+PYRIMETHAMINE IMPROVED THE CT APPEARANCE.
5 (LMS)	28	DRUG-USER	SPINAL MYOCLONUS	TUBERCULOUS MYELOPATHY	5 MONTHS	ENMG: MYOCLONIC JERKS EEG: NORMAL CSF: AFS POSITIVE	MILD IMPROVEMENT OF THE PARAPLEGIA WITH ANTITUBERCULOUS DRUGS.
6 (CS)	35	HOMOSEXUAL	LEFT HEMICHOREA-HEMIBALLISM	CNS TOXOPLASMOSIS	NONE	CT: MASS LESION ON THE RIGHT BASAL GANGLIA	SULFADIAZINE+PYRIMETHAMINE IMPROVED THE CT APPEARANCE BUT THE INVOLUNTARY MOVEMENT IMPROVED WITH THIORIDAZINE.
7 (AB)	34	HOMOSEXUAL	RUBRAL TREMOR	CNS TUBERCULOSIS AND TOXOPLASMOSIS	21 MONTHS	CT: MASS LESIONS ON CEREBELLAR HEMISPHERES AND MIDBRAIN	ANTITUBERCULOUS AND ANTITOXOPLASMOSIS DRUGS IMPROVED THE CT APPEARANCE.



**Fig. 1.** Case 1. A and B: CT scan showing ring-enhancement lesions in both frontal lobes. C and D: marked improvement 2 weeks after toxoplasmosis treatment.



**Fig. 2. Case 7. A:** CT scan showing mass lesion in the left cerebellar hemisphere and midbrain. **B:** high-density lesions without mass effect, six months after treatment.

rifampin, isoniazid and pyrazinamide was initiated with mild improvement of the paraplegia and the myoclonus.

**Patient 6. CS,** a 35-year-old homosexual man presented with choreic movements in the left side of the body including the face. An anti-HIV test was positive and a CT scan showed low-density lesion in the right basal ganglia. He was treated with pyrimethamine and sulfadiazine and the lesion improved but not the abnormal involuntary movement. Two years later he developed intracranial hypertension and an MRI showed mass lesions in the right frontal lobe and left parietal and occipital lobes. The biopsy revealed a primary lymphoma of the CNS. He was treated with radiotherapy with dramatic improvement. At this time thioridazine was initiated with marked improvement of the choreic movements.

**Patient 7. AB,** a 34-year-old homosexual man had the diagnosis of AIDS since 1990. In 1992 he developed signs and symptoms of intracranial hypertension. The CT scan showed mass lesions in the left cerebellar hemisphere and midbrain (Fig. 2 A). The biopsy of the cerebellar lesion showed a tuberculous granuloma. He was treated with rifampin, isoniazid and pyrazinamide with a marked improvement of the neurologic symptoms. Toxoplasmosis abscess developed in rabbit brain after inoculation with the material obtained from the biopsy. Six months later he developed a proximal unilateral tremor of the left arm that appeared only when the arm was outstretched. It had a great amplitude suggesting that the tremor had a rubral origin. A CT scan showed high-density lesions without mass effect in the left cerebellar hemisphere and midbrain (Fig. 2 B).

#### COMMENTS

Since 1984 cases of AIDS-related movement disorders have been described<sup>7,11,12</sup>. In 1987, Nath et al.<sup>10</sup> were the first to focus these movements in AIDS patients. Several movements have been reported such as hemichorea-hemiballism<sup>1,3,7,9,10,12-15</sup>, myoclonus<sup>10,11</sup>, dystonia<sup>8,10,18</sup>, parkinsonism<sup>2,8,10</sup>, tremor<sup>5,10,11,15</sup> and cerebellar ataxia<sup>15</sup>.

We observed 7 AIDS patients with abnormal involuntary movements being 3 with parkinsonian features, 2 with hemichorea-hemiballism, 1 with spinal myoclonus and 1 with rubral tremor. In the parkinsonian patients, opportunistic

infection was not responsible for the symptoms neither the use of neuroleptic drugs. The loss of the substantia nigra neurons seen in patients with AIDS encephalopathy is probably due to the HIV virus itself<sup>4</sup>. Speculatively, this could be responsible for the higher susceptibility to neuroleptic drugs in AIDS patients. It is possible that the parkinsonian features, found in our patients were related to the HIV virus, as in patient 3 of Nath et al.<sup>10</sup>. The patient 1 in their report was probably due to Whipple's disease of the CNS. Toxoplasmosis abscess as a cause of parkinsonism was reported by Carrazanna et al.<sup>2</sup>. Recently, an akinetic-rigid syndrome associated with HIV-related progressive multifocal leukoencephalopathy was also described<sup>16</sup>. In our patients the treatment with levodopa resulted in improvement of the parkinsonian features but, because of the severe side effects, it had to be withdrawn. Putatively, the side effects occurred because of the interaction with other drugs as AZT, sulfadiazine and many others used as prophylactic agents.

The main cause of hemichorea-hemiballism reported in AIDS patients has been toxoplasmosis abscess<sup>3,7,10,12-14</sup>. Cabral et al.<sup>1</sup> reported a patient in which the etiology of the choreic movements was a cryptococcal granuloma. Our patients (patients 1 and 6) presented choreic movements as their first manifestation of AIDS. Both had cerebral toxoplasmosis. The patient 6 also presented choreic movements involving one side of the face, as seen in the report of Nath et al.<sup>9</sup>. This type of involuntary movement appears early in the course of the AIDS and in the majority of the cases it does not improve with the treatment for toxoplasmosis despite of the radiological improvement which is in accordance to our experience<sup>9</sup>.

The patient with myoclonic jerks (patient 5) presented with a progressive radiculomyelopathy. Since the myoclonus were seen only in the lower limbs and the EEG was normal it had probably a spinal origin. Tuberculosis was suggested as the cause of the paraplegia because of the CSF examination and the improvement with antituberculosis drugs. We found another 2 patients with myoclonus in the literature<sup>10</sup>. Only the patient 3 had spinal origin, probably triggered by laminectomy, but as the disease progressed an underlying spinal disease was suggested.

Finally, the patient 7 had postural tremor which was unilateral, affecting the proximal part of the arm, and had a great amplitude. This, together with the lesions in the midbrain and cerebellar hemisphere suggests that the tremor had a rubral origin, as seen in the report of Koppel et al.<sup>5</sup>. A peculiar factor is the presence of two opportunistic infections occurring at the same time in this patient. The movements were first interpreted as focal seizures, and carbamazepine was initiated. The tremor disappeared 6-8 weeks later.

Although uncommon, the abnormal involuntary movements in AIDS patients may occur in many different forms and be secondary to opportunistic infections or the HIV virus. Our 3 parkinsonian patients apparently did not have any opportunistic infection in connection with the neurological symptoms, but in the remaining four patients this relationship was considered.

The diagnosis of AIDS and in particular cerebral toxoplasmosis must be considered in young patients with hemichorea-hemiballism.

The data suggest that not only the opportunistic infection but also the AIDS virus may play an important role in the development of movement disorders.

#### REFERENCES

1. Cabral NL, Becker N, Teive HAG, Werneck LC. Hemi-coreia por granuloma fúngico em paciente aids: relato de caso. *Arq Neuropsiquiatr* 1992; 50(Supl):171.
2. Carrazanna E, Rossitch E, Samuels MA. Parkinsonian symptoms in a patient with AIDS and cerebral toxoplasmosis. *J Neurol Neurosurg Psychiatry* 1989; 52:1445-1446.
3. Fonseca LC, Tedrus GMA, Albertin MC. Balismo como manifestação inicial de síndrome de imunodeficiência adquirida: relato de caso. *Arq Neuropsiquiatr* 1992; 50(Supl):145.
4. Hriso E, Kuhn T, Masdeu JC, Grundman M. Extraparalymidal symptoms due to dopamine-bloking agents in patients with AIDS encephalopathy. *Am J Psychiatry* 1991; 148: 1558-1561.

5. Koppel BS, Daras M. Rubral tremor due to midbrain toxoplasmosis abscess. *Movement Disord* 1990, 5:254-256.
6. Levy RM, Bredesen DE, Rosenblum ML. Neurological manifestations of the acquired immunodeficiency syndrome (AIDS): experience at UCSF and review of the literature. *J Neurosurg* 1985, 62:475-495.
7. Martínez-Martín P. Hemichorea-hemiballism in AIDS. *Movement Disord* 1990, 5:180.
8. Metzger WS. Movement disorders with AIDS encephalopathy: case report. *Neurology* 1987, 37:1438.
9. Nath A, Hobson DE, Russell A. Movement disorders with cerebral toxoplasmosis and AIDS. *Movement Disord* 1993, 8:107-112.
10. Nath A, Jankovic J, Pettigrew C. Movement disorders and AIDS. *Neurology* 1987, 37:37-41.
11. Navia BA, Jordan BD, Price RW. The AIDS dementia complex: I. Clinical features. *Ann Neurol* 1986, 19:517-524.
12. Navia BA, Petito CK, Gold JWM, Cho E, Jordan BD, Price RW. Cerebral toxoplasmosis complicating the acquired immune deficiency syndrome: clinical and neuropathological findings in 27 patients. *Ann Neurol* 1986, 19:224-238.
13. Pestre P, Milandre L, Farnarier P, Gallais H. Hémichorée au cours du syndrome d'immunodéficience acquise: abcès toxoplasmiques dans le striatum. *Rev Neurol (Paris)* 1991, 147:833-837.
14. Sanchez-Ramos JR, Factor SA, Weiner WJ, Marquez J. Hemichorea-hemiballism associated with acquired immune deficiency syndrome and cerebral toxoplasmosis. *Movement Disord* 1989, 4:266-273.
15. Singer C, Berger J, Weiner W, Sanchez-Ramos J. Movement Disorder in acquired immunodeficiency syndrome. *Movement Disord* 1991, 6:275.
16. Singer C, Berger JR, Bowen BC, Bruce JH, Weiner WJ. Akinetic-rigid syndrome in a 13-year-old girl with HIV-related progressive multifocal leukoencephalopathy. *Movement Disord* 1989, 4:266-273.
17. Sohler MP. Manifestações neurológicas da síndrome de imunodeficiência adquirida. Tese de Mestrado (UFF), 1991.
18. Tolge CF, Factor SA. Focal dystonia secondary to cerebral toxoplasmosis in a patient with acquired immune deficiency syndrome. *Movement Disord* 1991, 6:69-72.
19. Vergara TRC, Carvalho JJF, Oliveira CAB, Gonçalves AJR. Manifestações neurológicas da síndrome de imunodeficiência adquirida. *Arq Bras Med* 1986, 60:173-190.