

OVESCO remOVE system for easy removal of over-the-scope clips – a practical case

Ana Catarina **CARVALHO**, Francisco **PIRES**, Sofia **VENTURA**, Ricardo **ARAÚJO**, António **CASTANHEIRA** and Ricardo **CARDOSO**

Received: 20 May 2022

Accepted: 25 May 2022

We report a case of a 72-year-old man with a signet-ring gastric antrum adenocarcinoma that underwent total gastrectomy with Y-de-Roux procedure. The surgery was complicated by a severe dehiscence of the esophagojejunal anastomosis with perianastomotic abscess a week later. Endoscopic treatment was not considered feasible at the time. The patient underwent surgical drainage of the perianastomotic abscess, was started on broad-spectrum antibiotics and a jejunostomy was performed for feeding. Clinical evolution was favorable and endoscopic reevaluation after two months revealed an improvement of the anastomotic dehiscence, with only a 10 mm orifice remaining (FIGURE 1). In this regard, it was decided to place a fully covered self-expandable metallic stent, anchoring its proximal end with an over-the-scope clip (OTSC). Both stent and OTSC positions were confirmed by

fluoroscopy and the patient was discharged asymptomatic 2 weeks after the procedure.

Five weeks after the procedure, the patient presented to the emergency department with abdominal pain and abdominal computed tomography scan revealed distal migration of the stent. The upper gastrointestinal endoscopy unveiled an intact but substenotic esophagojejunal anastomosis (FIGURE 2) and the migrated stent was visualized in a jejunal loop. However, the extraction was unsuccessful due to the inability to pass the OTSC through the substenotic anastomosis. Therefore, the OTSC clip cutter remOVE system® (Ovesco Endoscopy AG, Tübingen, Germany) was used to split the OTSC in two fragments ([E-VIDEO*](#)), thus allowing the removal of the stent without complications (FIGURE 3). The patient was discharged asymptomatic two days after the procedure.

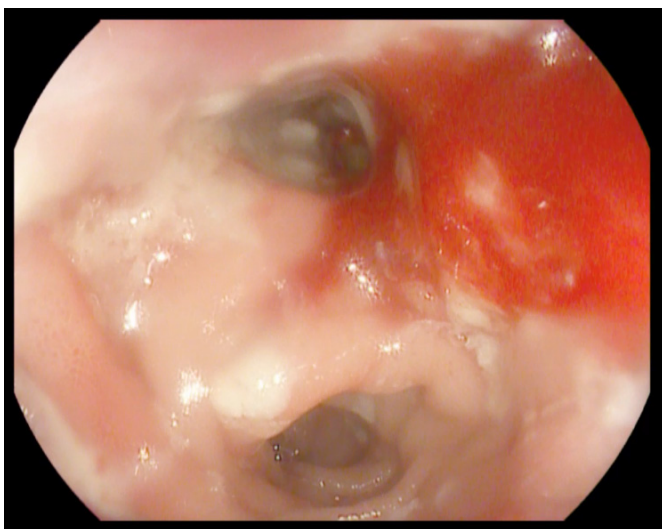


FIGURE 1. After 2 months of conservative management, upper gastrointestinal endoscopy revealed an improvement of the anastomotic dehiscence, with only a 10 mm orifice.

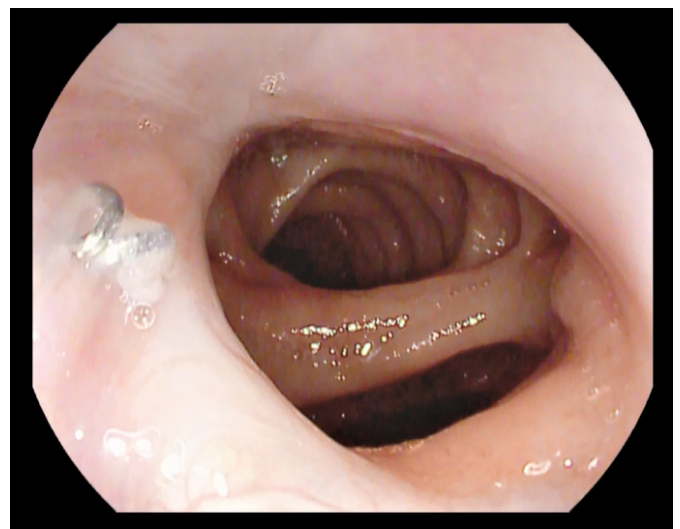


FIGURE 2. Five weeks after endoscopic placement of a fully covered self-expandable metallic stent, upper gastrointestinal endoscopy unveiled an intact but substenotic esophagojejunal anastomosis.

Declared conflict of interest of all authors: none

Disclosure of funding: no funding received

Department of Gastroenterology, Centro Hospitalar Tondela-Viseu, E.P.E., Viseu, Portugal.

Corresponding author: Ana Catarina Guedes Beleza Carvalho. E-mail: anacatarina54@gmail.com

*E-VIDEO: https://youtu.be/N41_qVBEWqA

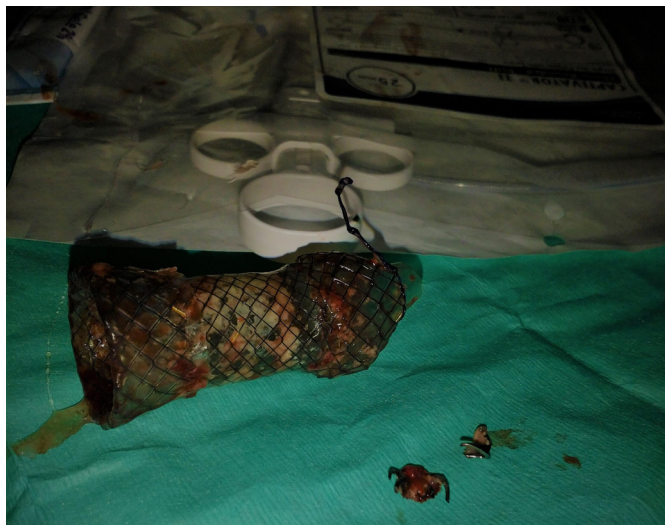

FIGURE 3. Using the over-the-scope clip clip cutter remOVE system, the over-the-scope clip stentfix was split in two fragments, allowing the removal of the stent.

The OTSC is an endoscopic device used for several purposes, including prevention of stent migration⁽¹⁾. Endoscopic methods for its removal have different success rates and associated adverse events⁽²⁾. The remOVE system is effective and easy to use, allowing safe removal of OTSC⁽³⁾.

Authors' contribution

Carvalho AC: acquired data, drafted the manuscript and performed video edition. Pires F and Ventura S: acquired data and performed image edition. Araújo R and Castanheira A: responsible for conception and performance of the endoscopic procedure and critically revised the report. Cardoso R: critically revised the report. All authors read and approved the final version of the manuscript.

Orcid

Ana Catarina Carvalho: 0000-0001-6536-8381.
Francisco Pires: 0000-0001-9104-484X.
Sofia Ventura: 0000-0002-9401-1901.
Ricardo Araújo: 0000-0002-7645-1161.
António Castanheira: 0000-0002-4861-7267.
Ricardo Cardoso: 0000-0002-9838-4342.

Carvalho AC, Pires F, Ventura S, Araújo R, Castanheira A, Cardoso R. Sistema OVESCO remOVE para a remoção de OTSC – um caso prático. *Arq Gastroenterol.* 2022;59(3):447-8.

REFERENCES

1. Mudumbi S, Velazquez-Aviña J, Neumann H, Kyanam Kabir Baig KR, Mönkemüller K. Anchoring of self-expanding metal stents using the over-the-scope clip, and a technique for subsequent removal. *Endoscopy.* 2014;46:1106-9.
2. Ou YH, Kong WF, Li LF, Chen PS, Deng SH, He FJ, et al. Methods for Endoscopic Removal of Over-the-Scope Clip: A Systematic Review. *Can J Gastroenterol Hepatol.* 2020;2020:1-10.
3. Bauder M, Meier B, Caca K, Schmidt A. Endoscopic removal of over-the-scope clips: Clinical experience with a bipolar cutting device. *United Eur Gastroenterol J.* 2017;5:479-84.